

Gripper it and Rip it – A Dual Arch Tray Technique for a Single Posterior All-Ceramic Crown

Edward Lowe, BSc., DMD, Kobus Steyn, RDT

Whether you call them triple trays, check bite trays or dual arch trays, the use of these quadrant posterior trays to take definitive impressions are a vital element of a dentist's armamentarium.

The advantages include ease of use, convenience, comfortable for the patient, use of less impression material, and time savings. Some of the challenges with this type of tray have been patient comfort, poor impression results, operator errors, patient biting on the tray, and patient biting through the tray.

This article will go through the steps for preparing and placing a single posterior IPS Empress pressed porcelain crown. The focus will be on taking a successful impression with a new dual arch tray on the market called

“The Gripper Tray” (Discus Dental, Culver City, CA) (Fig. 1).

The Gripper's super rigid design makes it ideal for all VPS impressions applications. For added accuracy, the Posterior tray features a unique patent pending composite/metal hybrid design for the ultimate in rigidity and patient comfort. Each handle grip is made with a matte finish that can be written on for easy patient identification and date recording. This is helpful not only in the practice but also in the laboratory. The Gripper trays are easy to use and provide exceptional results. Available in an assortment of dual arch impression trays (anterior, full arch, full arch large, $\frac{3}{4}$ arch and posterior), each features a large handle for superior placement, low side walls and a soft-lined mesh for exceptional impression accuracy.

PATIENT HISTORY AND TREATMENT PLAN

A female patient in her mid-twenties presented with a large



FIGURE 1—The Gripper trays.

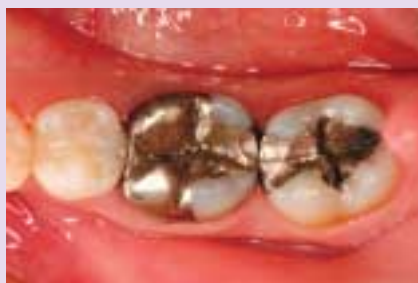

FIGURE 2—Pre-Operative view of existing amalgam restorations on 4.6 and 4.7.

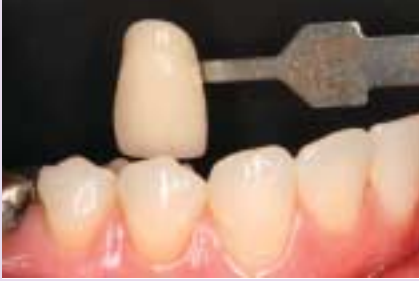

FIGURE 3—Shade selection with Chromoscop shade guide.

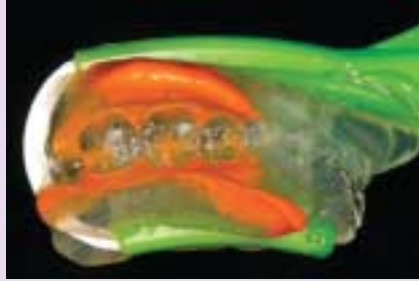

FIGURE 4—Pre-operative impression of existing dentition for provisional fabrication.

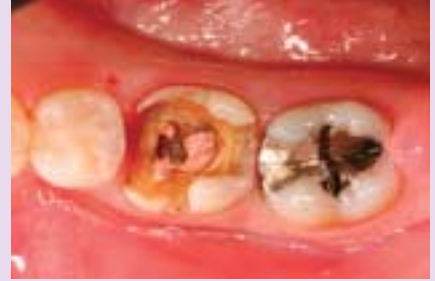

FIGURE 5—Recurrent decay and amalgam removed in 4.6.

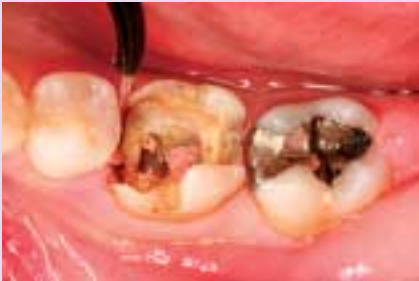

FIGURE 6—Soft tissue diode laser used to expose mesial margin.

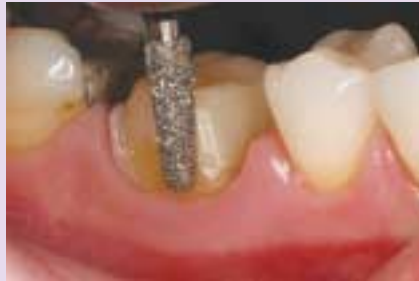

FIGURE 7—Crown preparation with the Zip! RSC 856-025.

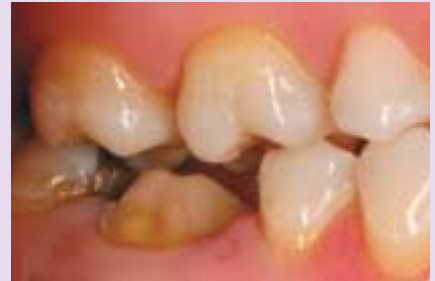

FIGURE 8—The preparation is checked for adequate occlusal clearance.

MODBL amalgam restoration on tooth #4.6 and an MO amalgam on tooth # 4.7 (Fig. 2).

She had endodontic therapy on tooth #4.6 over 7 years prior and the radiographs show no significant findings. Her extraoral exam and TMJ exam was uneventful and her occlusion is sound. Her clinical intraoral exam revealed a healthy oral environment as she had been seeing her dentist for regular oral exams and hygiene. Quadrants 1, 2, and 3 had been previously restored with direct composites and indirect ceramic restorations.

The treatment plan is conservative. The amalgam on both teeth will be removed. Tooth #4.6 will be built up with composite and prepared for an IPS Empress (Ivoclar Vivadent, Amherst, NY) pressed porcelain crown. Tooth #4.7 will be restored with a direct composite resin restoration.

PREPARATION APPOINTMENT

Treatment began with digital

photos of the adjacent teeth. It was determined with the Chromoscop shade guide (Ivoclar Vivadent, Amherst, NY) that the shade of the restoration will be a body shade of 040 and cervical 110 (Fig. 3).

A pre-op impression of the existing restorations was taken with a light body vinyl polysiloxane impression material (Precision, Discus Dental, Culver City, CA) and a Gripper tray lined with a clear bite registration material (Peppermint Snap, Discus Dental, Culver City, CA) (Fig. 4). The teeth were isolated with a rubber dam and the amalgam restorations were removed with a 1557 carbide bur. A caries detector was used to check for recurrent decay. The preparations were cleaned with hydrogen peroxide and dried with a steady stream of air (Fig. 5).

A soft tissue laser (Odyssey, Ivoclar Vivadent, Amherst, NY) was used to remove excess interproximal gingival tissue and expose the prep margin. A small

trough was made with the laser alongside the tooth to ensure replication of the margin in the dental laboratory (Fig. 6). The tooth was etched and bonded with a dual cure bonding agent (Cabrio CQ, Discus Dental, Culver City, CA) and built up with a flowable and posterior microhybrid composite (Matrixx, Discus Dental, Culver City, CA). The tooth was prepped for a crown using a super coarse and a fine round end taper diamond (RSC 856-021 and RF 856-016 Zip! Diamond Burs, Discus Dental, Culver City, CA) (Fig. 7). Finishing was completed using finishing disks (Soflex XT, 3M, St. Paul, MN). The finished prep was checked for adequate occlusal clearance (Fig. 8), smooth tapering walls, and visible margins (Fig. 9).

The Gripper quadrant posterior tray was used to take the impression using Precision Extra Light Body and Medium body VPS (Discus Dental, Culver City, CA). The extra light body was injected around the dried crown prepara-

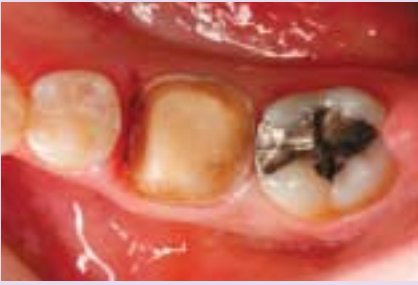

FIGURE 9—The prep walls and margins are visually inspected.

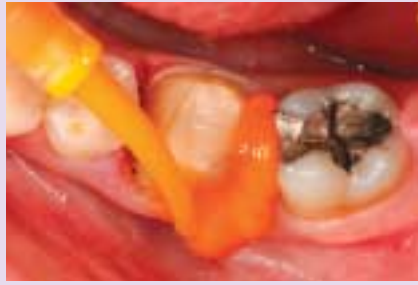

FIGURE 10—Light body impression material is placed around the prep.

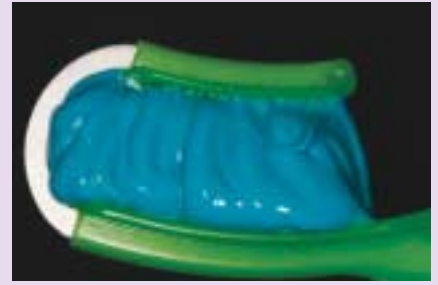

FIGURE 11—Medium body impression material is dispensed in the tray.

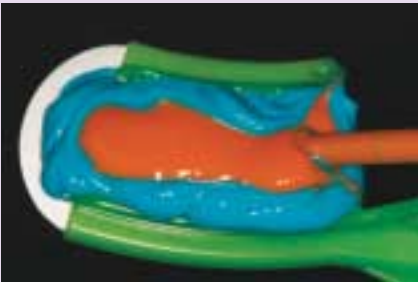


FIGURE 12—A layer of light body material is injected into the medium body.

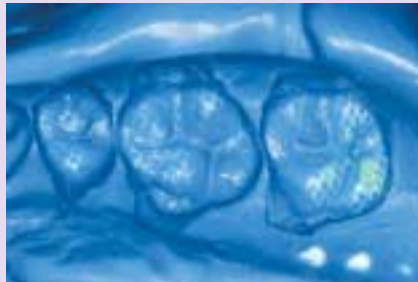


FIGURE 13—Heavy body impression showing pulls and voids.

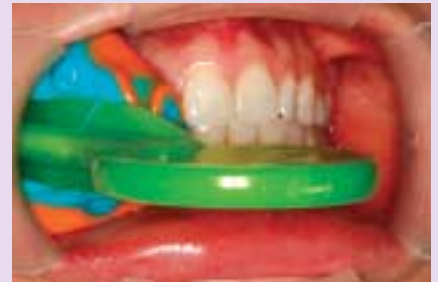

FIGURE 14—The impression is placed with the See More retractors in place.

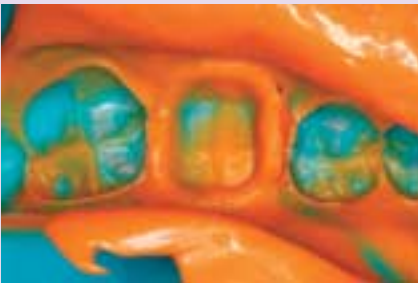

FIGURE 15—Replication of the margins in the impression is verified.

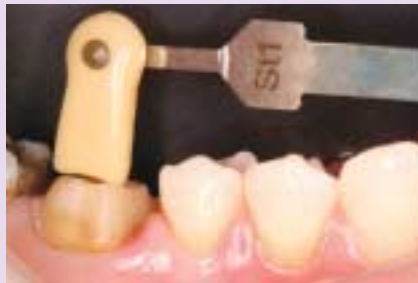

FIGURE 16—The prep shade is recorded.

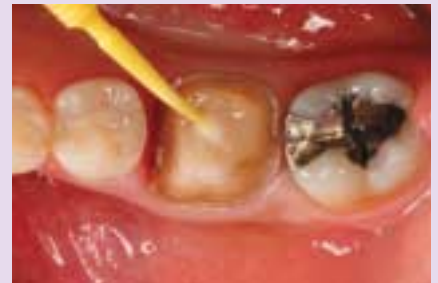

FIGURE 17—Glycerin is applied to the buildup before acrylic provisional fabrication.

tion (Fig. 10) while the assistant loads the tray with medium body (Fig. 11). When the tray is loaded, the lower viscosity extra light body is injected into the centre of the higher viscosity medium body like a wiener in a hot dog bun on both sides of the dual arch tray (Fig. 12). This “Hot Dog” technique minimizes pulls and drags which often occur when using a higher viscosity PVS material in the heavy body or putty / wash technique (Fig. 13). The tray is positioned over the teeth to be impressed using self-retracting lip retractors (SeeMore, Discus Dental, Culver City, CA) for isola-

tion and visibility. The patient gently closes over the tray and bites into the PVS without biting the sides of the tray (Fig. 14). The impression is checked for accurate detail and absence of bubbles, pulls, and drags (Fig. 15). The preparation shade of ST1 is recorded and photographed (Fig. 16). A bite registration was taken with a VPS material (Vanilla Bite, Discus Dental, Culver City, CA) to help ensure the accuracy of the mounting.

A small amount of glycerin gel (Liquid Strip, Ivoclar Vivadent, Amherst, NY) is applied to the

buildup area of the crown preparation to prevent adhesion of the acrylic provisional material (Fig. 17). A self-curing acrylic resin shade A1 (Perfectemp II, Discus Dental, Culver City, CA) is added to a pre-operative impression of the existing restorations (Fig. 18). After a 2 minute setting time, the provisional is gently teased off the tooth and finished outside the mouth with finishing disks and polishers (Fig. 19). It is cemented on the clean and dried tooth prep with a dual cured provisional cement (Provolink, Ivoclar Vivadent, Amherst, NY) (Fig. 20). The occlusion is adjusted and the

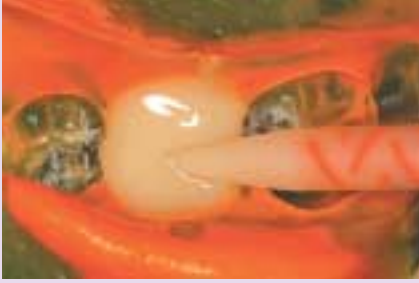

FIGURE 18—Self-curing acrylic resin is added to pre-op impression of existing restorations.

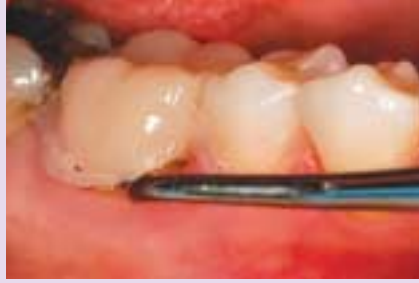

FIGURE 19—The acrylic provisional is gently lifted off for finishing.

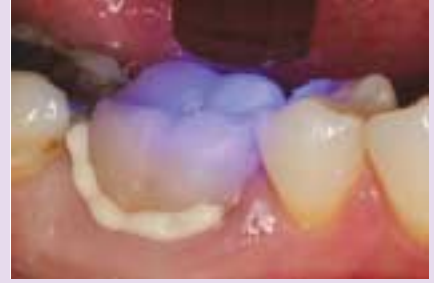

FIGURE 20—The finished provisional crown is cemented with provisional cement.

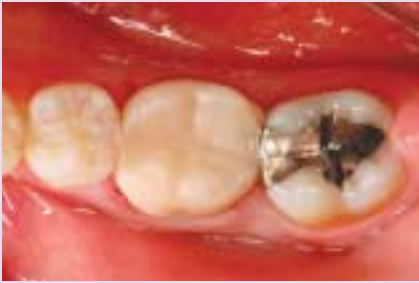

FIGURE 21—The completed provisional.

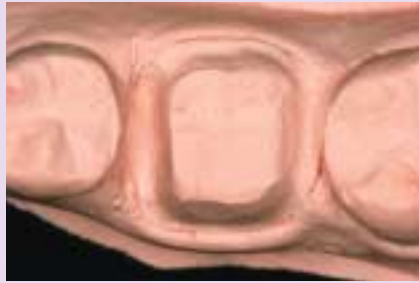

FIGURE 22—The margins of the preparation in the uncut model.

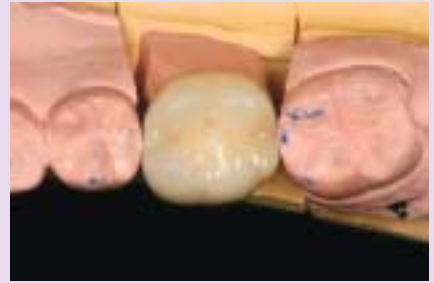

FIGURE 23—The IPS Empress crown on the working model.

patient is dismissed (Fig. 21).

The lab was provided with the impressions and bite records, a detailed lab prescription, digital photos, and shade using shade match software (Easyshade, Vident, Brea, CA).

FROM THE LABORATORY PERSPECTIVE (KOBUS STEYN, RDT)

To a lab advantages such as convenience, comfort, material savings and time savings comes second to the accuracy factor. After all if you don't have the time and money to do it right in the first place, where will you get the time and money to do it right the second time?

First impressions are always lasting. The design of the Gripper tray is impressive. The Gripper is made from a composite/metal hybrid. This keeps the impression from flexing when removed from the mouth and models, preventing distortion with high and tight fitting crowns as a result.

The wide handle grip makes it easy to hold and control when pouring the die stone. Being able to write on the handle grip makes it very practical for lab use.

The margins of the preparation were great. There were no air bubbles or dragging to be seen. The margins were quite clean even in the deep interproximal areas where the tissue was removed by laser. The Extra Light body and the Medium body of the Precision VPS Impression material flowed together to become one single rigid impression.

We used Whip Mix Prima die stone to pour the crown and bridge model. First, the pinned model was poured, then the opposing model with the crown and bridge model still in the impression.

On inspection of the articulated models from the buccal and lingual it was clear that the models were in perfect occlusion. The

teeth were spot on in contact on the wear facets.

A solid model was poured to verify the margins and the mesial and distal contacts (Fig. 22). The crown fitted perfect on the working as well as the solid model (Fig. 22). This was a sign that there no distortion of the impression occurred when the models were removed.

Both the Gripper tray and the Precision VPS together form a good rigid unit. It is firm enough for the model to be removed without distorting the impression. Yet it is flexible enough to prevent the model from breaking when removing it from the tray.

Being a skeptic of dual arch trays, I must admit that I am thoroughly impressed with the Gripper. Not only did it meet the criteria of comfort, convenience, material saving and time saving, but it proved to be impressively accurate. This makes it a valu-

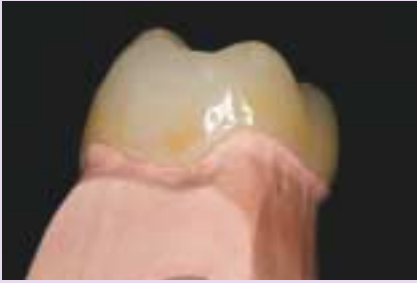

FIGURE 24—Marginal adaptation to the working die is verified.

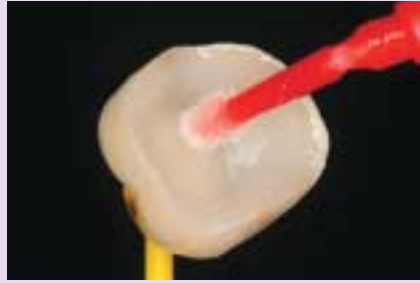


FIGURE 25—Bonding agent is added to the inside of the etched and silanated crown.

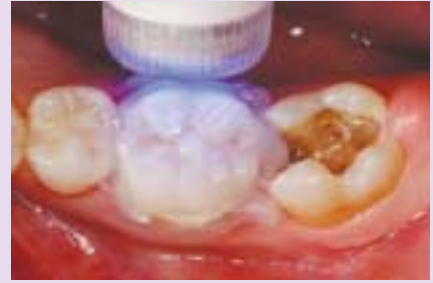

FIGURE 26—Final cure with the Flashlite 1401 and glycerin on the margins.

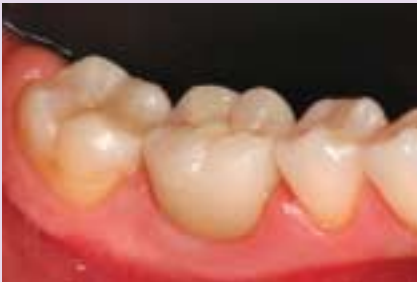

FIGURE 27—The completed view of #4.6 crown and #4.7 MO from the buccal.

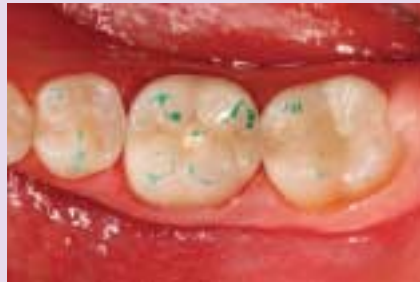

FIGURE 28—The occlusion is checked.

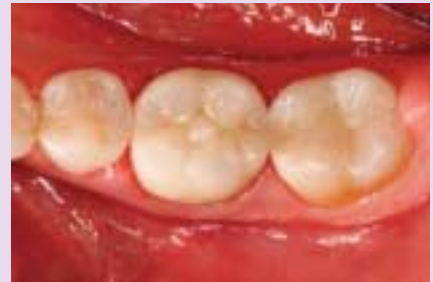

FIGURE 29—The immediate post operative occlusal view of #4.6 and #4.7.

able tool in our constant pursuit of excellence and predictable dentistry.

SEAT APPOINTMENT

The patient was given local anaesthetic and the old amalgam in tooth 4.7 removed. The new pressed porcelain crown is inspected for marginal fit, colour, and defects (Fig. 24). The temporary restoration was removed with a set of hemostats. The crown was tried in dry to ensure a proper fit and the margins were inspected and checked with an explorer.

The internal aspect of the crown was re-etched with 37 percent phosphoric acid for 15-20 seconds, rinsed with water and dried. This cleansed the porcelain surface of saliva, try-in paste, and debris. Silane (Monobond-S, Ivoclar Vivadent, Amherst, NY) was applied to the internal surface for 1 minute and lightly air dried. The silane acts as a coupling agent between the porcelain and the resin luting cement. Bonding

agent (Excite, Ivoclar Vivadent, Amherst, NY) was painted on the inside of the crown (Fig. 25). The solvent was evaporated using a steady stream of warm air.

The preparation was cleaned using a chlorhexidine solution. The composite buildup was micro-abraded with a micro-etcher to improve the adhesion to the resin luting cement. The entire crown prep was etched with a 37 percent phosphoric acid for a total of 15 seconds. The etch was rinsed off and excess water was removed using the high volume suction and a micro-tip applicator, leaving the tooth surface moist. A layer of bonding agent (Excite, Ivoclar Vivadent, Amherst, NY) was applied to the tooth and scrubbed into the tooth surface for 10 to 15 seconds. The solvent was evaporated using a warm air dryer for five seconds and the tooth prep checked for a uniform glossy layer on the tooth surface. The adhesive layer was cured with an LED curing light (Flashlite 1401, Discus Dental, Culver City,

CA) for 10 seconds.

The high value shade (transparent +1) of Appeal Dual Cure Posterior resin cement (Ivoclar Vivadent, Amherst, NY) was selected. The catalyst and base were mixed and applied into the prepared restoration and with a small brush. The restoration was transferred to the mouth using a Vivastick (Ivoclar Vivadent, Amherst, NY). The restoration was held down using a ball burnisher and spot tacked in place for two seconds using a 2mm tacking tip. The excess cement was removed using a rubber tip and floss. Liquid Strip glycerin gel (Ivoclar Vivadent, Amherst, NY) was placed on the margins and light cured for 40 seconds from each aspect (Fig. 26). The occlusion was checked and the crown polished using Soflex XP medium disks (3M ESPE, St. Paul, MN) and Astropol polishing points (Ivoclar Vivadent, Amherst, NY).

Seating the crown prior to the

placement of the direct composite facilitates the placement of the interproximal matrix and gives the clinician control over the size and tightness of the interproximal contact. The MO composite resin on #47 was completed using an A3 dentin shade and a transparent enamel shade (Tetric Evo Ceram, Ivoclar Vivadent, Amherst, NY) to match the all ceramic crown (Fig. 27). The occlusion was verified after finishing and polishing (Fig. 28). The contact points were checked with floss to ensure assess for hygiene.

The immediate post operative view of the restorations reveals a return to esthetic and functional harmony.

CONCLUSION

Single posterior crowns are the staple of the restorative dentist's diet. This article has outlined the use of a new dual arch posterior tray for impression taking and model preparation of a posterior pressed porcelain crown.

The VPS capture of multiple restorations using a dual arch tray should be approached with discretion. The technique is ideal for a single unit restoration where the prepped tooth has teeth in stable occlusion mesial and distal to it. The possibility of accurately replicating the inter-arch occlusal relationship decreases as the number of restorations attempted with one dual arch tray increases.

We are blessed to be offered so many dental innovations, making our clinical lives more enjoyable. Patients, dental technicians, and dentists all benefit from the advances in material science and procedures. It is truly a wonderful time to be practicing dentistry!

OH

Edward Lowe, BSc., DMD, is the clinical director of the Pacific Aesthetic Continuum. He is a clinical faculty member at the Dawson Center in St. Petersburg, FL and at the Pacific Implant Institute in Vancouver, BC. He maintains a full-time private practice devoted to comprehensive restorative and aesthetic dentistry in Vancouver, BC.

Kobus Steyn, RDT, finished a four-year diploma in Dental Technology in Pretoria, South Africa (SA) in 1980. He has worked and studied in South Africa, Great Britain, Australia, USA and Canada. He and his wife, Danita own Staindent Dental Lab in Grande Prairie, AB.

Oral Health welcomes this original article.

@ARTICLECATEGORY:583